



Atypical chronic rhinosinusitis in Papillon Lefevre syndrome: Presentation of Two cases

Juan Antonio Lugo¹, Ruth Salazar², Nadia Zavala³, Oscar Rodríguez⁴, Gerardo Vargas⁵, Lorenzo Lizárraga⁶, Alejandra Pineda⁷, Irene Arellano⁸, Pablo Luna⁹, Fernanda Barragán¹⁰, Mario Sepúlveda¹¹

¹ Associate Physician of the Department of Otolaryngology, Hospital de Especialidades No 2, Centro Médico Nacional del Noroeste, Instituto Mexicano del Seguro Social, Cd Obregón, Sonora, México

² Affiliated Physician of the Department of Pathological Anatomy. Hospital de Especialidades No 1, Centro Médico Nacional del Noroeste, Instituto Mexicano del Seguro Social, Cd Obregón, Sonora, México

³⁻¹¹ Resident Physician of the Department of Otolaryngology. Hospital de Especialidades No 2, Centro Médico Nacional del Noroeste, Instituto Mexicano del Seguro Social, Cd Obregón, Sonora, México

Abstract

Papillon-Lefevre syndrome (SPL) is an extremely rare autosomal recessive disorder characterized by palmoplantar keratoderma and periodontitis, with an estimated incidence of 1-4 cases per million. Patients with SPL are highly susceptible to infection. The etiology of this susceptibility is unknown; however, an association with defects in neurophilic dysfunction, insufficient response of lymphocytes, defects in monocyte functions and deterioration of cytotoxic function of NK cells has been suggested. The manifestations include oral cavity specifically at the dental level, however at the level of paranasal sinuses there is a singular manifestation little known, as our two cases. We propose the criteria of Lugo cols. for diagnosis

Keywords: atypical chronic rhinosinusitis, Papillon-Lefevre syndrome, criteria

Introduction

Papillon-Lefevre syndrome (SPLS) is an autosomal recessive disorder, with a prevalence ranging from 1 to 4 per million population. Papillon-Lefevre syndrome is characterized by premature loss of primary and permanent teeth and hyperkeratosis of the palms, plants and sometimes, knees and elbows. It is caused by mutations in the cathepsin C gene on chromosome 11q141, [2, 3]

The periodontal inflammation begins shortly after the eruption of the primary teeth, bone loss is rapid and severe; primary teeth are lost between three and five years of age and permanent teeth within a few years of the eruption. Detection of the lack of activity of urinary cathepsin C shortly after birth can allow early diagnosis, before tooth eruption and the development of periodontal disease [4]

The severity of the disease may be related to immunological and microbiological factors. Patients with Papillon-Lefevre have abnormalities in the function of neutrophils and natural killer cells. The molecular mechanisms involved in periodontal pathogenesis include poor processing and lack of cathelicidin in the gingival fluid. Organisms usually cultured from the gingival sulcus of patients with Papillon-Lefevre syndrome are similar to those cultured from children who have neutropenia and include *A. actinomycetemcomitans*, *Capnocytophaga* species, *Fusobacterium nucleatum*, *E. corrodens* and *Actinobacillus Aggregatibacter* [5, 6, 7].

The periodontal treatment recommended for young children with Papillon-Lefevre syndrome includes the identification of specific

periodontal pathogens and antibiotic therapy directed at these microorganisms [8, 9].

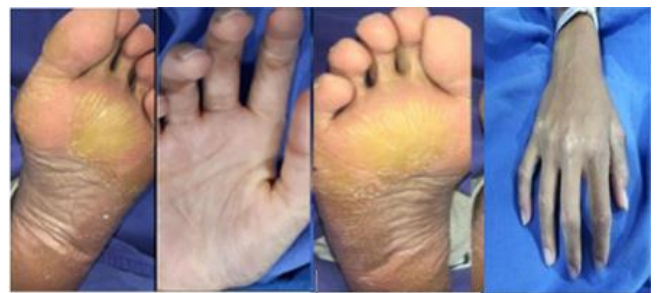

Fig 1: Palmoplantar hyperkeratosis is observed

In the paranasal sinuses little is known about their manifestations, these two cases were addressed by a possible fungal sinusitis, all because of the tomographic and transsurgical findings, however the histopathological results showed no presence of hyphae whatsoever and a neutrophilic infiltrate with a granulomatous response. Given a rare picture, we need to inform the medical community and invite others to report similar cases, if they have faced them and thus spread and increase our experience.

Clinical case NO 1.

Female, 28 years old, with palloplantar dyskeratosis, refers to starting 4 years previously with nasal obstruction, hyposmia,

nasal voice, retronasal discharge of yellow mucus, centrofacial headache, managed with antibiotics with multiple schemes without improvement, is sent for assessment, in the rinoscopia is functional septum, turbinates in cycle, yellowish secretion, oral cavity with absence of teeth, palm of the hands and soles of the feet with hyperkeratosis (figure 1 A), rest without important data Tomography with window for soft tissues, an occupation of the entire breasts is observed due to central hyperdense lesion, with bone expansion and remodeling, without apparent intracranial involvement (Figure 2A)

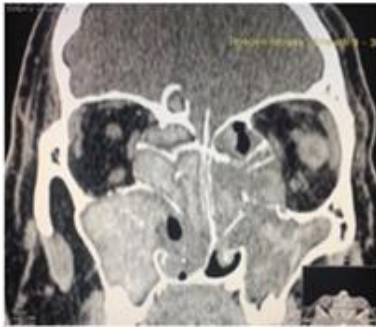


Fig 2

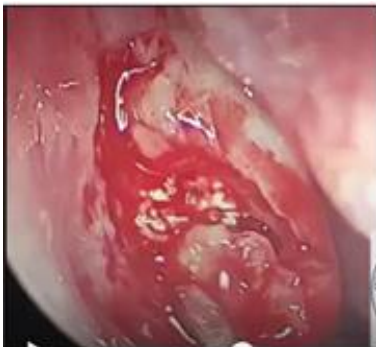

Fig 3

Intervened by endoscopic surgery of the nose and paranasal sinuses with probable diagnosis of fungal sinusitis, abundant whitish material of calcic appearance was found (3A surgery image), the paranasal sinuses are permeabilized and a histopathological study is sent where a granulomatous inflammatory process is described. With infiltration of abundant neutrophils, calcic areas with absence of fungi. (Histopathological Image 4 A)

Clinical case 2

A 26-year-old female patient was sent for a diagnosis of chronic sinusitis. She has a history of papillonle le fevré syndrome, treated with isotretinoin, previous adenoidectomy surgery and right eye chalazion. She began her condition 1 year ago with green rhinorrhea and a sensation of nasal congestion in the morning, accompanied by hyaline rhinorrhea, occasional sneezing, and mid-facial morning pain. She was treated with an antibiotic, giving green discharge, but remaining symptomatology persisted.

Nose with semipermeable nasal cavities with rosacea lesion at the level of the middle right meatus, not bleeding, partially

obstructing the nasal cavity, turbinates in the cycle, functional septum.

Oral cavity with total absence of teeth (clinical figure 1 B), keratosis knuckles of the hands and soles of the feet (Clinical Figure 2B), without other important data, simple nose tach and are:, observed in the maxillary sinus right occupation due to heterogeneous isodensity with probable intralesional calcifications, as well as osteitis of the maxillary sinus walls and discrete lysis of the medial wall of the maxillary sinus, extending to the right middle meatus. (Figure TC 3B)

Intervened by endoscopic surgery of the nose and sinuses with probable diagnosis of fungal sinusitis, where abundant whitish material of calcic appearance was found (surgery image 5B), the paranasal sinuses are permeabilized and a histopathological study is sent where it is described (histopathological image 6B)

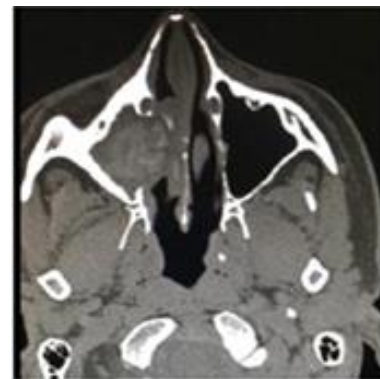


Fig 4

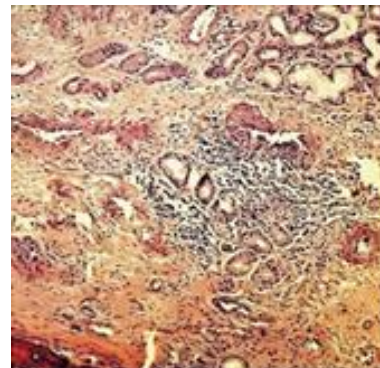


Fig 5

Simple CAT scan of the nose and paranasal sinuses, occupation of the cavities by hererogenic material and central calcic lesions, with expansion and remodeling, without intracranial extension

Discussion

A literature search was carried out in the databases LILACS, PUBMED, OVI, Google Scholar and SciELO with the following keywords: papillon -Le fevré and sunusitis or rhinosunusitis, locating only one article by the author Taejung Park, Boyoung Kim of Korea, by we consider it important to disclose our two cases. It is well known the implications of this disease at the skin and periodontal level, but in sinusitis, the papillon syndrome -Le fevré, has very particular characteristics that requires high

suspicion. In paranasal sinuses little is known about its manifestations, these two cases were addressed by possible fungal sinusitis, all because of the tomographic and transsurgical findings, similar to that reported by Taejung Park *et al.* 1 However, the histopathological results showed no presence of hyphae at all and a neutrophilic infiltrate with a granulomatous response. Given a rare picture, we need to inform the medical community and invite others to report similar cases, if they have faced them and thus spread and increase our experience

Conclusion

Patients with papillon syndrome -Le fevré apparently have a chronic sinusitis picture of particular characteristics, that the image and surgical findings give us a false orientation that it is a fungal sinusitis, however, the histopathological aspects no evidence content of hyphae, but a neutrophilic infiltrate and granulomatous tissue

For this reason, we propose that in a patient who presents as a base disease a papilloma syndrome Le fevré and clinical-radiological findings compatible with a chronic rhinosinuitis, consider a chronic granulomatous rhinosinuitis with neutrophilic infiltration.

We propose the following *Lugo Cols.* criteria. for the diagnosis of chronic granulomatous rhinus mucosa: papillon syndrome-Le fevré¹, simple paranasal sinus tomography in window for soft tissues with findings of hyperdense occupation, of calcic appearance involving one or more sinuses², trans-surgical findings of whitish lesions such as cheese³, and the histopathological results that exclude the presence of hyphae and confirm granulomas with neutrophilic infiltrate⁴, for the diagnosis it requires to count with the 4 criteria, so its management does not require antifungals and it will only be limited to surgical treatment to confirm the histopathological diagnosis.

References

1. Taejung Park, Boyoung Kim, A Case of Atypical Maxillary Sinusitis Accompanied with Papillon-Lefevre Syndrome, Korean Journal of Otorhinolaryngology-Head and Neck Surgery. 2013; 56(7):456-459.
2. Firatli E1, Tüzün B, Efeoğlu A. Papillon-Lefèvre syndrome. Analysis of neutrophil chemotaxis. Send to J Periodontol. 1996; 67(6):617-20.
3. Ghaffer KA1, Zahran FM, Fahmy HM, Brown RS. Papillon-Lefèvre syndrome: neutrophil function in 15 cases from 4 families in Egypt. Send to Oral Surg Oral Med Oral Pathol Oral Radiol Endod. 1999; 88(3):320-5.
4. Hamon Y1, 2,3,4, Legowska M5, Fergelot P6,7,8, Dallet-Choisy S1,2, Newell L9, Vanderlynden *et al* Analysis of urinary cathepsin C for diagnosing Papillon-Lefèvre syndrome, FEBS J. 2016; 283(3):498-509. doi: 10.1111/febs.13605. Epub 2016 Jan 4.
5. Eick S, Puklo M, Adamowicz K, Kantyka T, Hiemstra P, Stennicke H. *et al.* Lack of cathelicidin processing in Papillon-Lefèvre syndrome patients reveals essential role of LL-37 in periodontal homeostasis, Orphanet J Rare Dis. 2014; 27(9):148. doi: 10.1186/s13023-014-0148-y.
6. Preus H, Gjermo P. Clinical management of prepubertal periodontitis in 2 siblings with Papillon-Lefèvre syndrome,

J Clin Periodontol. 1987; 14(3):156-60.

7. Wiebe CB1, Häkkinen L, Putnins EE, Walsh P, Larjava HS. Successful periodontal maintenance of a case with Papillon-Lefèvre syndrome: 12-year follow-up and review of the literature, J Periodontol. 2001; 72(6):824-30.
8. Tinanoff N1, Temprow P, Maderazo EG. Dental treatment of Papillon-Lefèvre syndrome: 15-year follow-up Send to, J Clin Periodontol. 1995; 22(8):609-12.
9. Kressin S1, Herforth A, Preis S, Wahn V, Lenard HG, Papillon-Lefèvre. *et al.* syndrome--successful treatment with a combination of retinoid and concurrent systematic periodontal therapy: case reports, Quintessence Int. 1995; 26(11):795-803.